

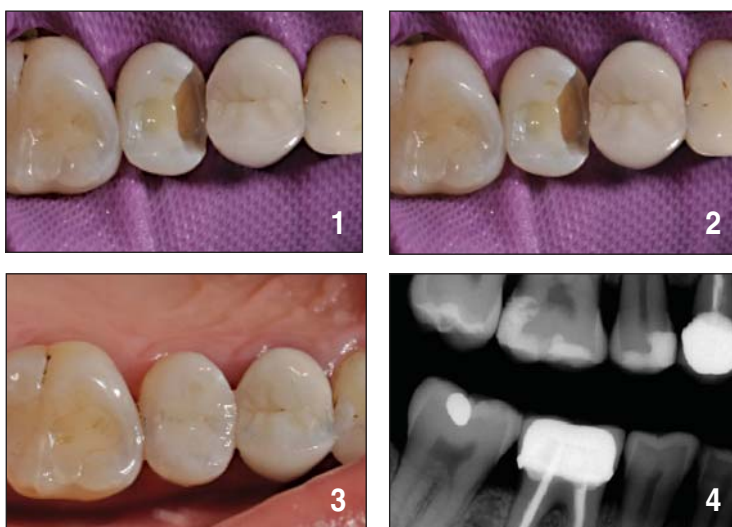
CASE STUDY

Slide #1: Intraoperative Class II preparation on 15MO with Roeko non-latex rubber dam isolation (Coltene).

Slide #2: Immediate post-operative result demonstrating superb chameleon effect and biomimicry of ClearFil Majesty Posterior A2 shade (single shade chameleon effect demonstration).

Slide #3: Clearfil Majesty Posterior A2 shade restoration in situ after occlusal adjustments.

Slide #4: Post-operative bitewing radiographs showing superb radiopacity of Clearfil Majesty Posterior and clear removal of all caries.



DR. CLARENCE TAM

HBSc, DDS, Cosmetic and General Dentistry



kuraray

CLEARFIL MAJESTY™ Posterior



KY-281_ Syringes (4.9g) or PLT's (20 x 0.25g)

\$104.00
per kit

CLEARFIL MAJESTY™ Esthetic



KY-28_ Syringes (3.6g) or PLT's (20 x 0.26g)

\$97.00
per kit

CLEARFIL MAJESTY™ Flow



KY-281_ Syringes (3.2g) and 15 Needle Tips

\$97.00
per kit

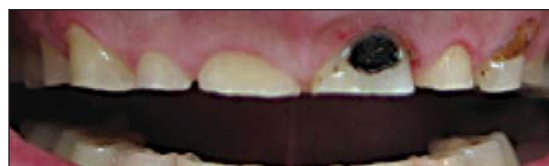CLEARFIL™ AP-X



KY-282_ Syringes (4.6g) or PLT's (20 x 0.26g)

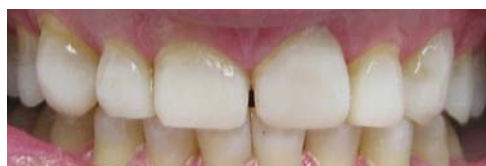\$72.00
per kit

CASE STUDY



Patient presented with multiple deep dentine exposure, very close to exposing pulp. No history of pulpitis as yet. Diagnosed with severe parafunctional habits, mix of grinding and clenching.

Offered options of full mouth rehab from 16-25 and 35-46 in Crowns (mix of PFMs and eMax) or in composite resin. Opted for composite resin on grounds of cost and to preserve more dental tissues.



Upper built up first over 4 hours chair time. Using Kuraray Clearfill SE bond system and Clearfil.

Majesty composite in shades OA2 for anteriors and OA3 for posteriors. OVD increase by approx 2.5mm.

Lower built up second over 4 hours chair time.

Using exact same materials, technique, shade etc. OVD increase by approx 1.5mm.

Minor occlusal adjustment over 2 weeks.

Bite splint fabricated.

DR. JUNGIN PARK

BDS Otago NZ

